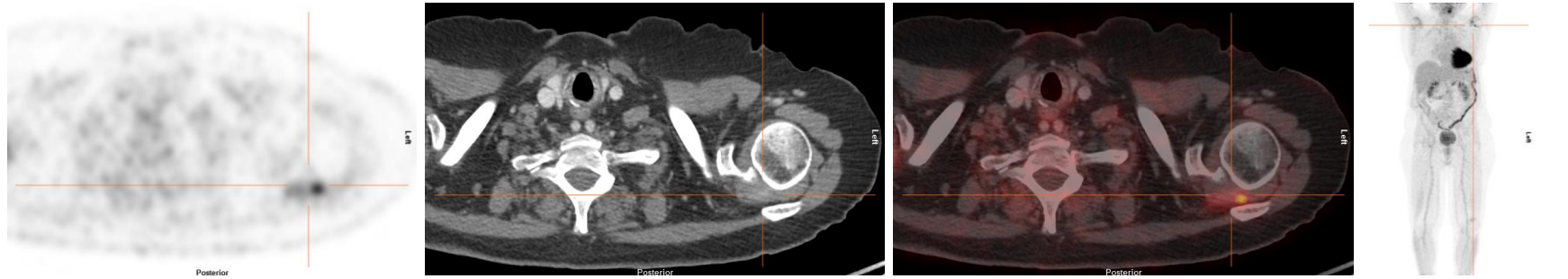
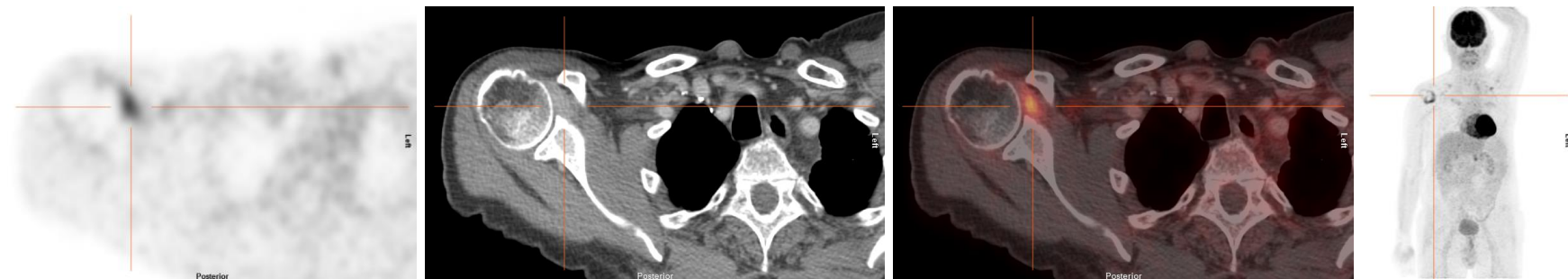


Supplemental figure. Signs of CPI-induced arthritis in conventional CT, ^{18}F -FDG PET and PET-CT.



Patient 4, left shoulder



Patient 9, right shoulder

Figure legend: ^{18}F -FDG PET, CT, PET-CT fusion image and 3D MIP of PET for two patients showing both contrast enhancement on conventional CTs as well as focal FDG uptake in the joint, marked by the crosshair.