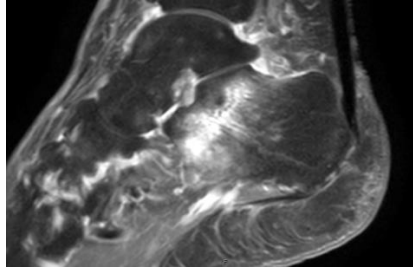
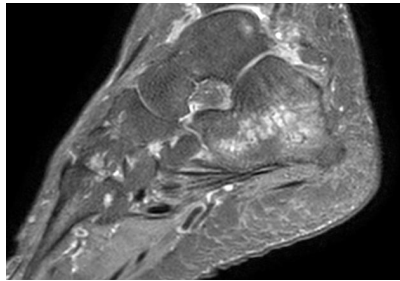


Supplemental Figure 2

MRI of the right foot at the time of the occurrence of the first fracture



(T1-weighted imaging)



(T2-weighted imaging)