

Online Supplementary File S1: Example of patient vignettes

The patient vignettes in Set 1 included an introduction about the patients' age, sex, body mass index (BMI), symptom duration, acute (<48 hours) and chronic (6 weeks) pain and stiffness in hand joints, duration of morning stiffness in fingers and thumb base joints, other hand symptoms such as locking, numbness and tingling, pain in other joints, other diseases such as psoriasis and inflammatory bowel disease, and OA and psoriasis in family. The section about clinical examination findings included information about bony enlargement, soft tissue swelling, dactylitis and tenosynovitis in the hands, and pain on palpation or movement of other joints. If available, laboratory results including C-reactive protein (CRP), erythrocyte sedimentation rate (ESR), rheumatoid factor, anti-cyclic citrullinated peptide (anti-CCP) and uric acid levels were described. Lastly, hand radiography results included information about osteophytes, joint space narrowing (JSN), central erosions and marginal erosions.

All patients in Sets 2 had symptoms in the interphalangeal and/or thumb base joints, depending on whether the exercise was for overall hand OA, interphalangeal OA and thumb base OA.

Furthermore, no other disease or acute injury should explain their symptoms. The patient vignettes in Sets 2 included information about the proposed criteria only.

Example of patient vignette in Set 1

Anne is a 63-year old slim (BMI 20 kg/m²) woman with inflammatory back pain for at least 25 years. She has long-lasting morning stiffness of 3 hours in both fingers and thumb base joints. She is telling her rheumatologist that she has experienced pain for more than 6 weeks in bilateral DIP2-3, left DIP4, right DIP5, bilateral IP1, bilateral PIP2-3, bilateral MCP1, left MCP5 and bilateral thumb base joints. The same joints plus right DIP4 and right PIP5 have also been stiff in the same period. She has previously performed surgery of the left 4th-5th finger due to contractures of these fingers. The 5th finger was later partly amputated due to severe contractures and deformities. She has still locking of other fingers. Anne has also diffuse numbness and tingling of the fingers. She has several other painful joint areas including the neck, upper, middle and lower back, both shoulders, right elbow, both wrists, both hips, right knee, both ankles and toes in both feet. She has no psoriasis herself, but is aware of psoriatic arthritis and OA in close family members.

Clinical examination findings:

- Bony enlargement of bilateral DIP2-3, right DIP5, bilateral IP1, right PIP2-5, right MCP1 and bilateral CMC1.
- Pain on palpation or movement of all DIP, PIP and bilateral CMC1.
- Soft tissue swelling in the bilateral DIP2-3, bilateral IP1, bilateral PIP2-3, right PIP4 and left CMC1. No dactylitis or tenosynovitis.
- Pain on palpation or movement of neck, upper, middle and lower back, both shoulders, both elbows, both wrists, both hips, both knees, both ankles and toes in both feet.

Laboratory results:

- Normal CRP (1 mg/L) and ESR (12 mm/hour).
- HLA B27 is negative.
- Uric acid within the upper normal range (5.8 mg/dL, 346 µmol/L).

Hand radiography results:

- Mild to severe osteophytes and JSN in all DIP joints except left DIP4 (only mild JSN).
Central erosions in left DIP2-3.
- Moderate osteophytes and mild JSN in IP1 bilaterally and small osteophytes in left PIP2 and right MCP1.
- Severe osteophytes and moderate to severe JSN in bilateral CMC1, and moderate osteophytes with normal joint space in bilateral STT.
- No marginal erosions in PIP, MCP and wrist joints.

Example of patient vignette in Set 2

Anna is a 61-year old woman. On most days the previous 6 weeks, she has suffered from pain in right DIP5 and right PIP3. She has no morning stiffness in fingers and thumb base joints.

On the hand radiograph, there are osteophytes in bilateral DIP2, right DIP5, left IP1 and right PIP3. JSN is present in right DIP2, right DIP5 and left CMC1.

Online Supplementary File S2: Proposed criteria and their categories to be tested in the 1000minds categorization survey for overall hand OA

1. Age

- Below 45 years
- 45-54 years
- 55-64 years
- 65 years and above

3. Morning stiffness *

- Long morning stiffness (more than 30 min)
- No morning stiffness
- Short morning stiffness (30 min or less)

5. Osteophytes **

- None
- 1-2 joint(s)
- 3-5 joints
- 6 or more joints

7. Symptomatic OA **

- None
- 1-2 joint(s)
- 3-5 joints
- 6 or more joints

2. Symptom duration *

- Less than 6 weeks
- 6 weeks to 6 months
- More than 6 months

4. Stiffness after rest/inactivity *

- Long-lived inactivity stiffness (more than 5 min)
- None
- Short-lived inactivity stiffness (5 min or less)

6. Joint space narrowing **

- None
- 1-2 joint(s)
- 3-5 joints
- 6 or more joints

8. Inflammatory biomarkers

- Normal CRP and ESR
- Elevated CRP, normal ESR
- Normal CRP, elevated ESR
- Elevated CRP and ESR

* In target joints (distal interphalangeal (DIP), proximal interphalangeal (PIP), first interphalangeal (IP1) and thumb base joints). ** In target joints (DIP, PIP, IP1 and first carpometacarpal joints). OA=osteoarthritis, CRP=C-reactive protein, ESR=erythrocyte sedimentation rate.

Online Supplementary File S3: Proposed criteria sets for interphalangeal OA and thumb base OA with the weight of each criterion and the categories within each criterion derived from the 1000minds Preferences survey

Interphalangeal OA:

Criteria	Mean weight
Age	
<ul style="list-style-type: none"> Below 45 years 	0
<ul style="list-style-type: none"> 45-54 years 	6.7
<ul style="list-style-type: none"> 55-64 years 	11.4
<ul style="list-style-type: none"> 65 years and above 	15.2
Duration or morning stiffness in DIPs, PIPs and IP1 joints	
<ul style="list-style-type: none"> Long (more than 30 minutes) 	0
<ul style="list-style-type: none"> None 	6.2
<ul style="list-style-type: none"> Short (30 minutes or less) 	11.1
Number of DIPs, PIPs and IP1 joints with osteophytes	
<ul style="list-style-type: none"> None 	0
<ul style="list-style-type: none"> 1-2 joint(s) 	13.6
<ul style="list-style-type: none"> 3-5 joints 	22.6
<ul style="list-style-type: none"> 6 or more joints 	30.6
Number of DIPs, PIPs and IP1 joints with joint space narrowing	
<ul style="list-style-type: none"> None 	0
<ul style="list-style-type: none"> 1-2 joint(s) 	10.2
<ul style="list-style-type: none"> 3-5 joints 	17.5
<ul style="list-style-type: none"> 6 or more joints 	23.5
Radiographic OA (osteophytes or joint space narrowing) in at least 50% of the joints (DIPs, PIPs and IP1), in which the person has experienced pain, aching or stiffness on most days in the previous 6 weeks	

- No 0
- Yes **19.5**

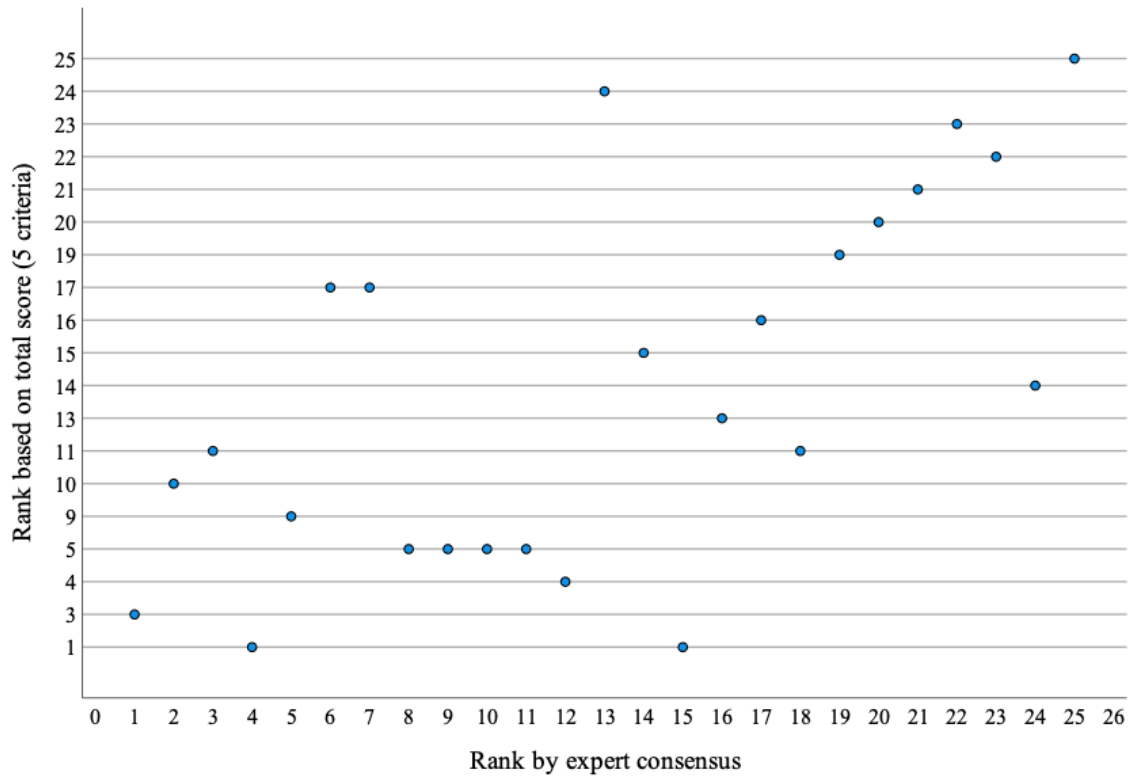
OA=osteoarthritis, DIP=distal interphalangeal, PIP=proximal interphalangeal, IP1=first interphalangeal

Thumb base OA:

Criteria	Mean weight
Age	
• Below 45 years	0
• 45-54 years	9.4
• 55-64 years	14.6
• 65 years and above	19.3
Duration or morning stiffness in thumb base joints	
• Long (more than 30 minutes)	0
• None	6.2
• Short (30 minutes or less)	13.1
Number of CMC1 joints with osteophytes	
• None	0
• 1 joint	15.2
• 2 joints	25.4
Number of CMC1 joints with joint space narrowing	
• None	0
• 1 joint	12.2
• 2 joints	22.5
Radiographic CMC1 OA (osteophytes or joint space narrowing) in the thumb base joints with pain, aching or stiffness on most days in the previous 6 weeks	
• No	0
• Yes	19.7

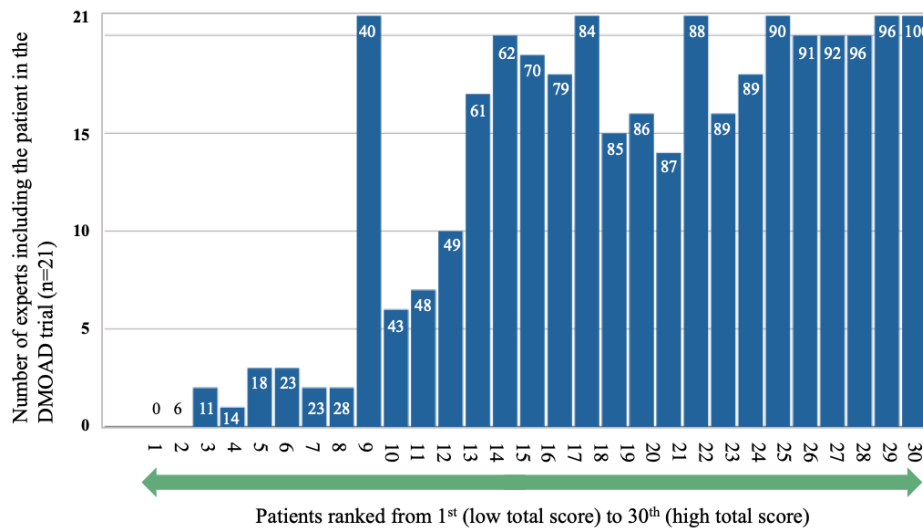
OA=osteoarthritis, CMC1=first carpometacarpal

Online Supplementary File S4: The concordance between the consensus rank (“pseudo-gold standard” and the rank based on the total criteria score (five criteria) in the first validity exercise.



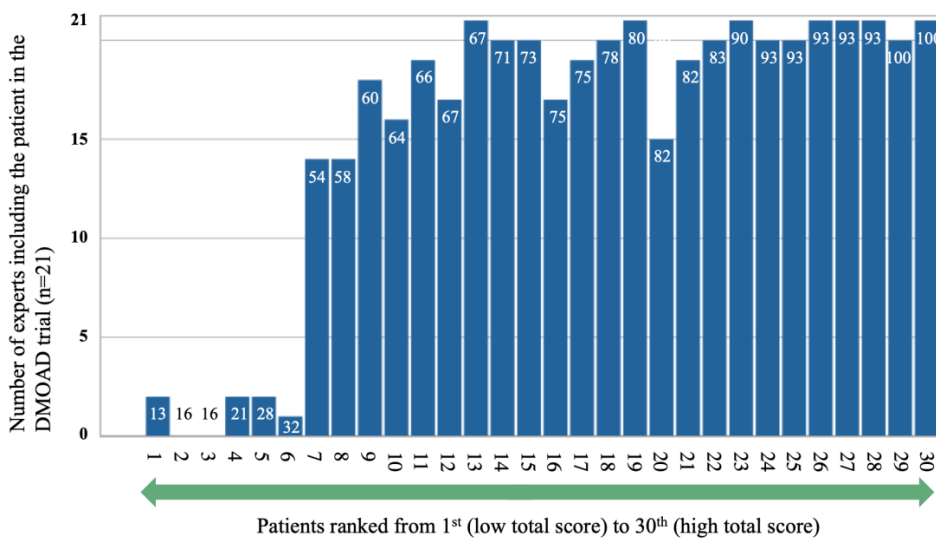
Online Supplementary File S5: Results from validity surveys for proposed interphalangeal OA and thumb base OA criteria sets

Interphalangeal OA:



DMOAD=disease-modifying osteoarthritis drug. The white numbers in the blue bars represent the total score (range 0-100) based on the criteria set presented in Online Supplementary File S3.

Thumb base OA:



DMOAD=disease-modifying osteoarthritis drug. The white numbers in the blue bars represent the total score (range 0-100) based on the criteria set presented in Online Supplementary File S3.